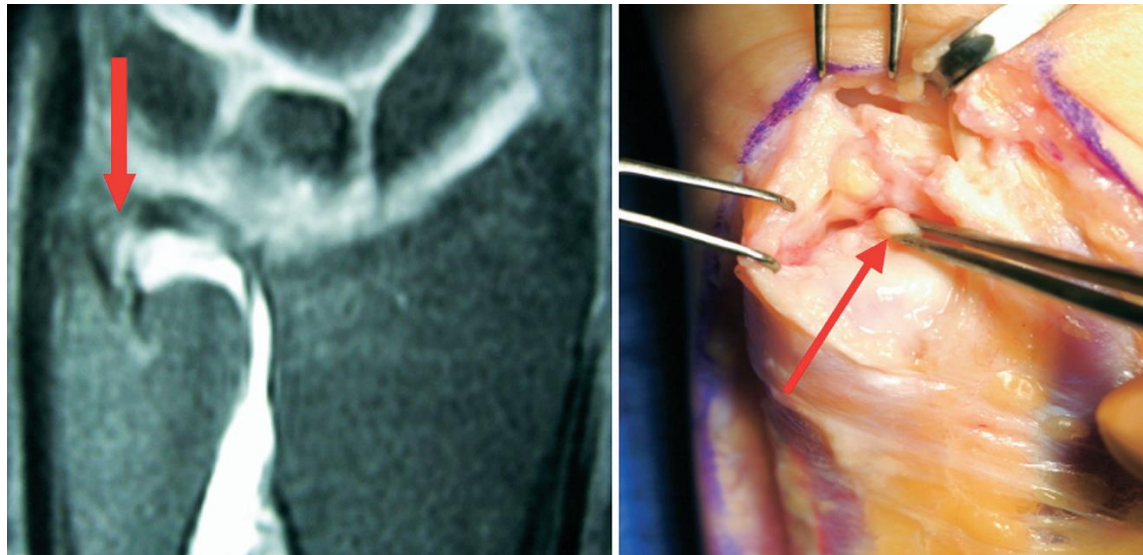


Anatomy and Biomechanics of the Distal Radio-Ulnar Joint



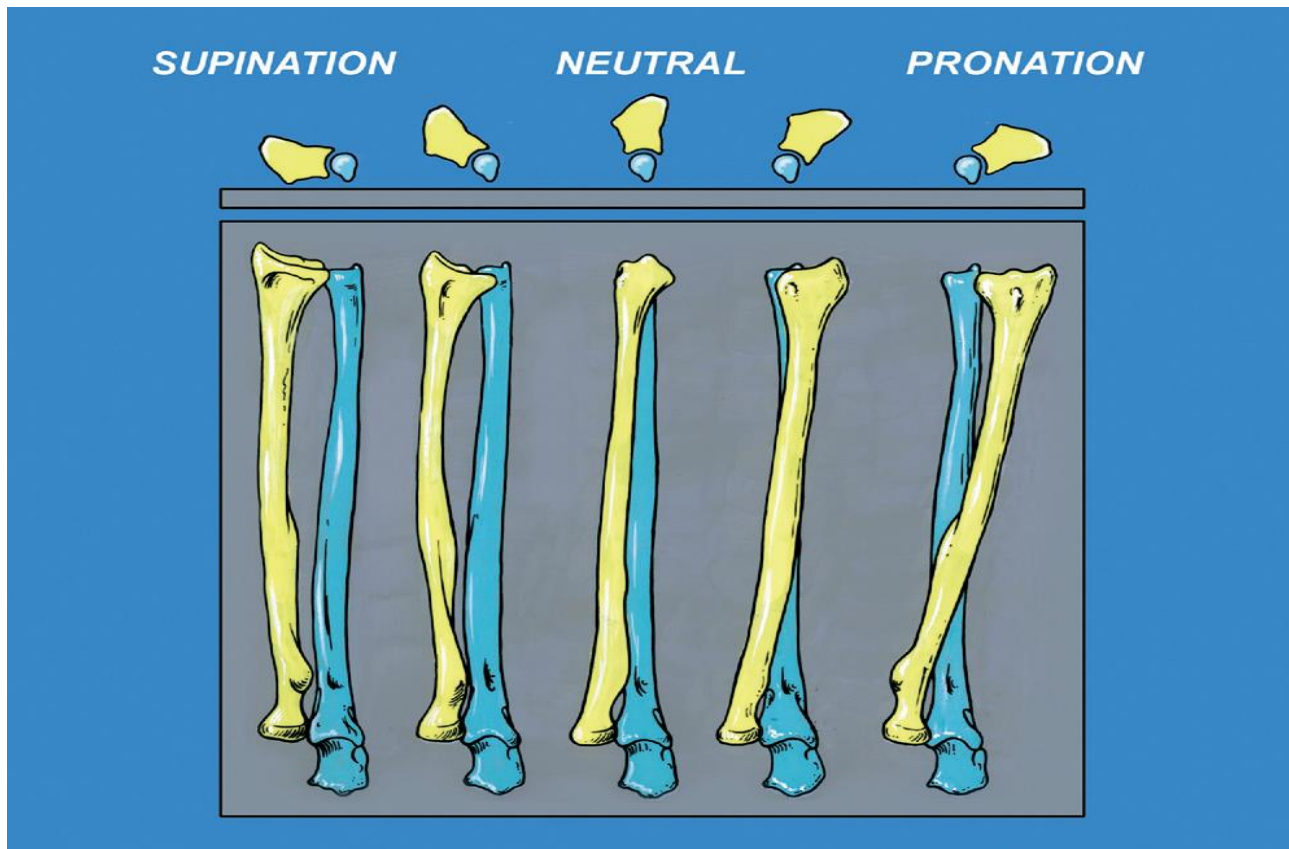
Dr. Andreas Panagopoulos, MD, Ph.D.

Upper Limb & Sports Orthopaedic Surgeon

Lecturer in Orthopaedics, Patras University Hospital

Contents

- ❑ Anatomy and Biomechanics of DRUJ
- ❑ Extrinsic & intrinsic stabilizers
- ❑ Clinical considerations
- ❑ Common problems
 - TFCC tears
 - ulnar impaction syndrome
 - DRJU instability
 - DRJU arthritis
- ❑ Interosseous membrane biomechanics



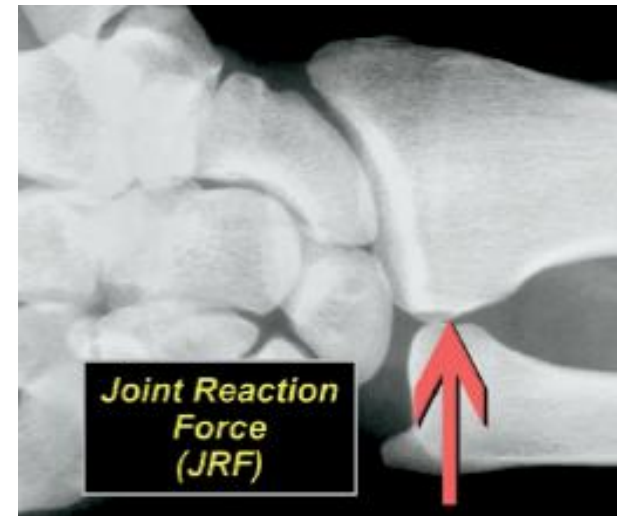
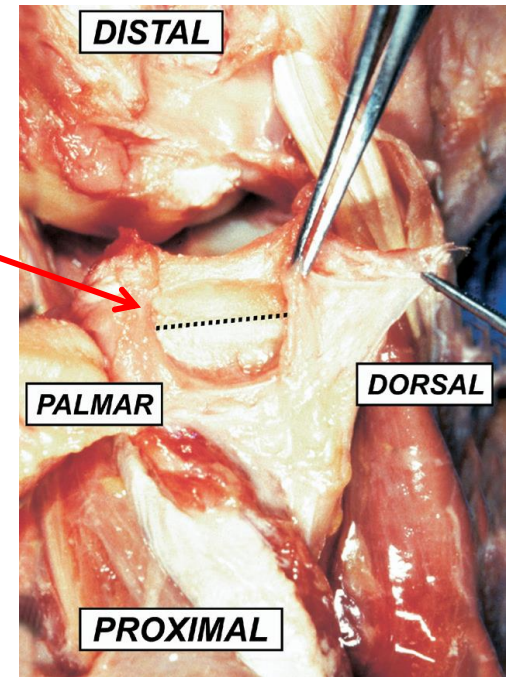
The anatomy of the sigmoid notch of the radius, the seat of the ulna and the guiding check-rein potential of the components of the TFC allow:

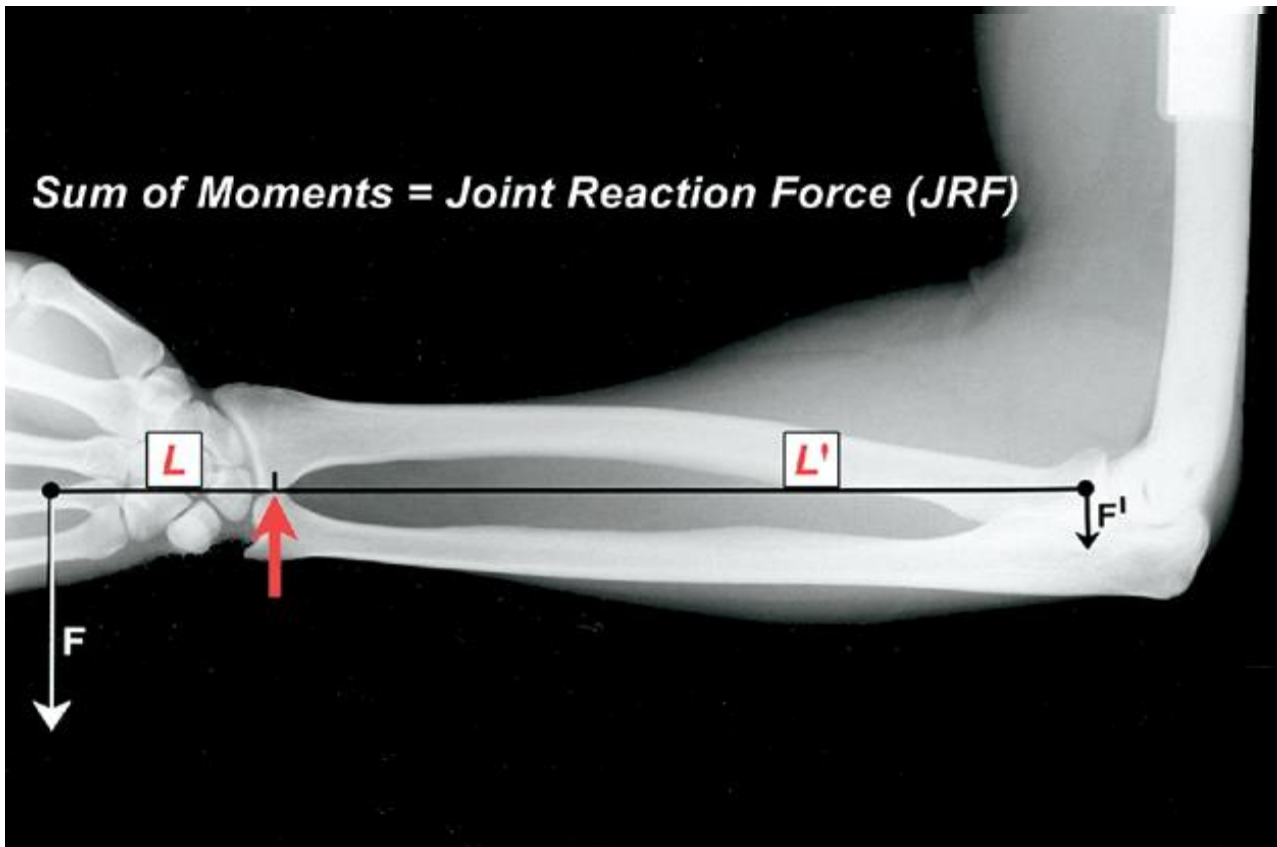
- 90° of forearm **supination**, at which point the two forearm bones are essentially parallel, and the interosseous space the widest, to 90° of **pronation**, at which point the radius has rotated across the anterior surface of the fixed ulna

The principal axis of load bearing tracks across the sigmoid notch from proximal/palmar in supination to distal/ dorsal in pronation.

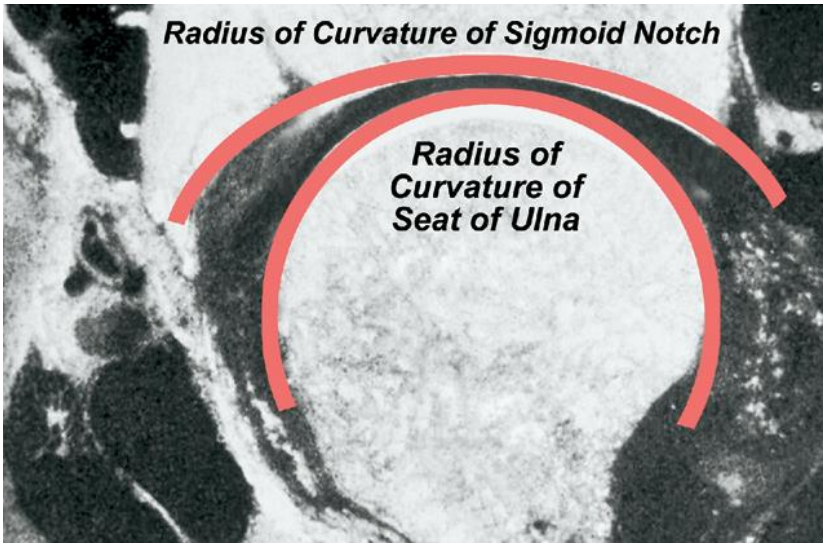
“zero-rotation” position of the forearm :

elbows at the side and flexed 90° (prepared for work), the radiocarpal unit rests “on top” of the ulna seat, with gravity pulling the hand and its load towards the ground.

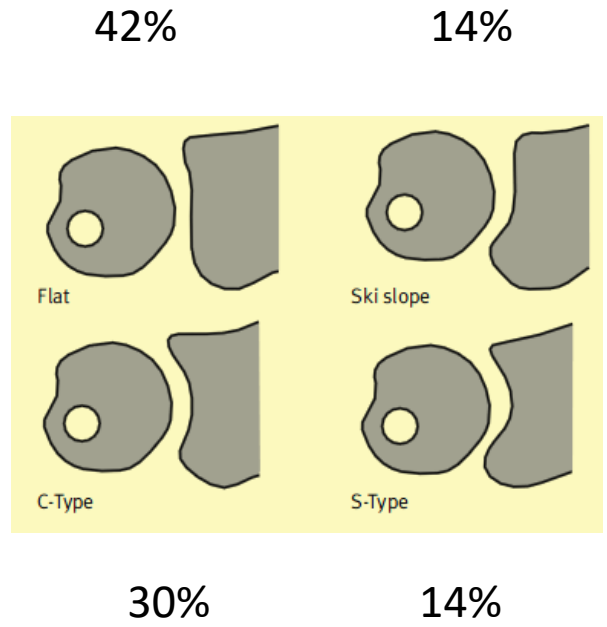

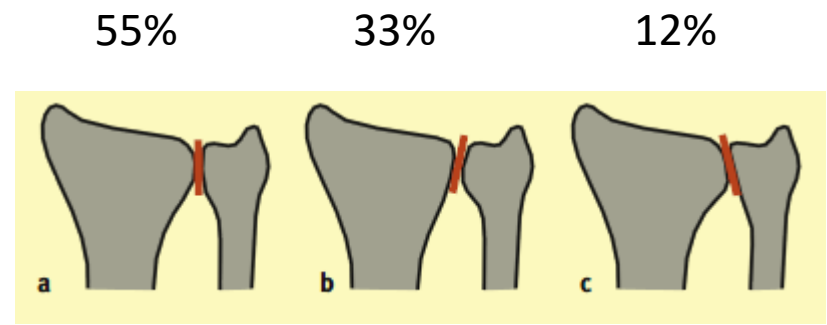




The sum of the moments on the distal and proximal sides of the fulcrum equal the joint reaction force (JRF) at the distal radioulna joint.

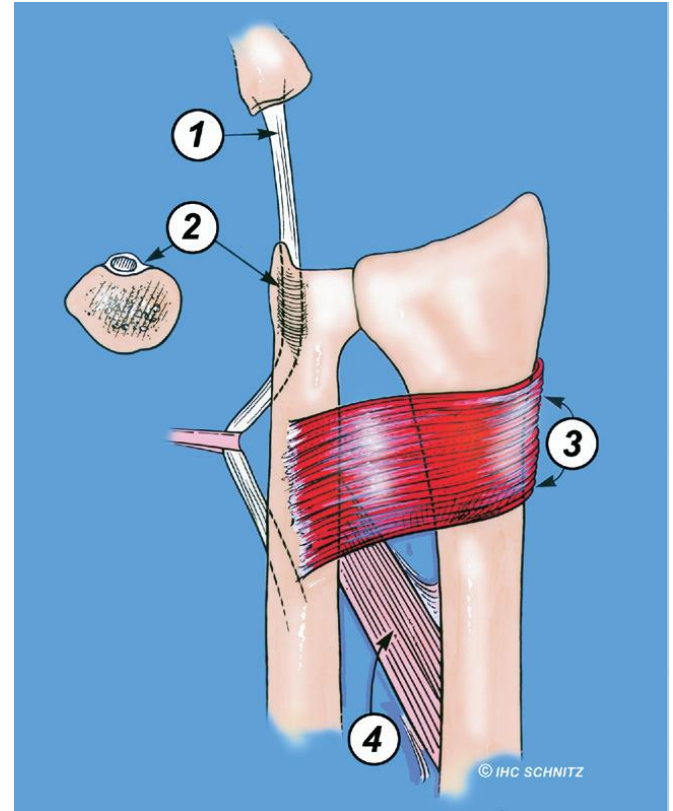


The radius of curvature of the sigmoid notch (15 mm) is greater than that of the ulna (10 mm), allowing both rotational and sliding motions in the normal joint.



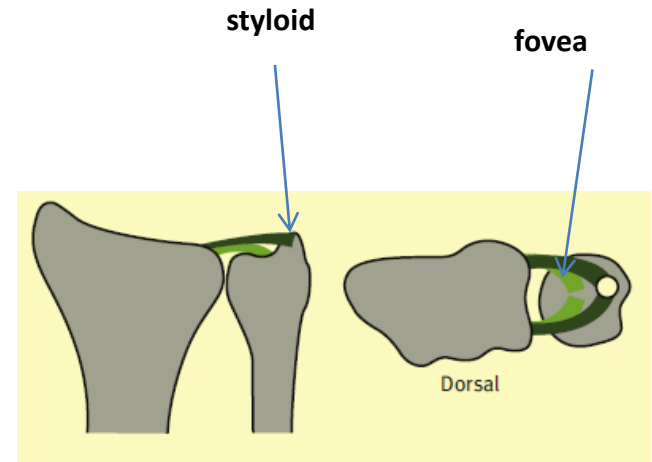
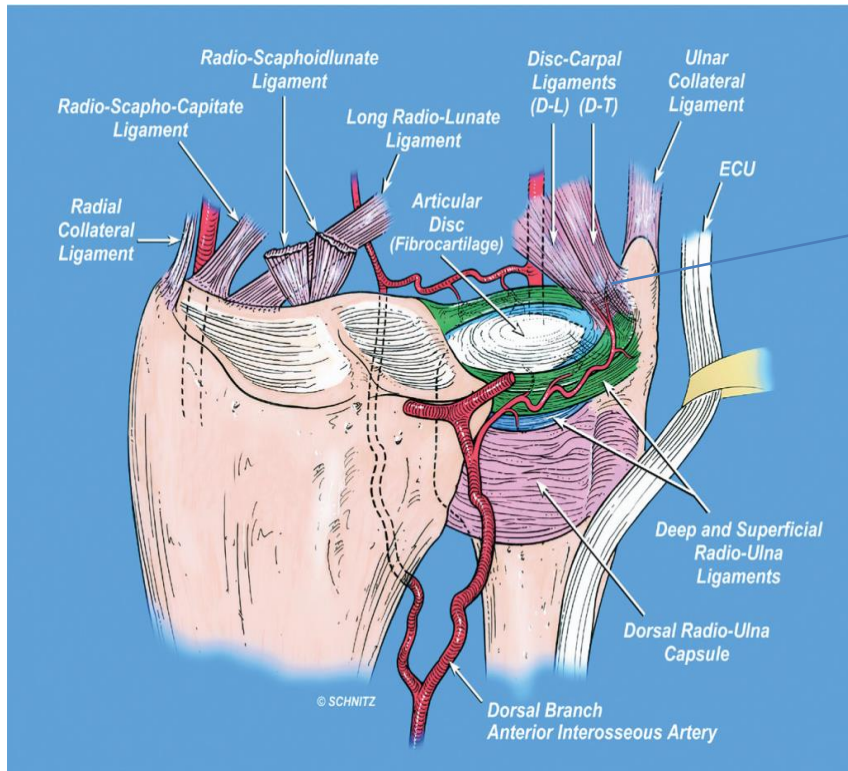
Extrinsic stabilizers

- (1) dynamic tensioning of the ECU
- (2) the semirigid sixth dorsal compartment subseath
- (3) the dynamic support provided by the superficial and deep heads of the pronator quadratus, and
- (4) the interosseous ligament of the midforearm



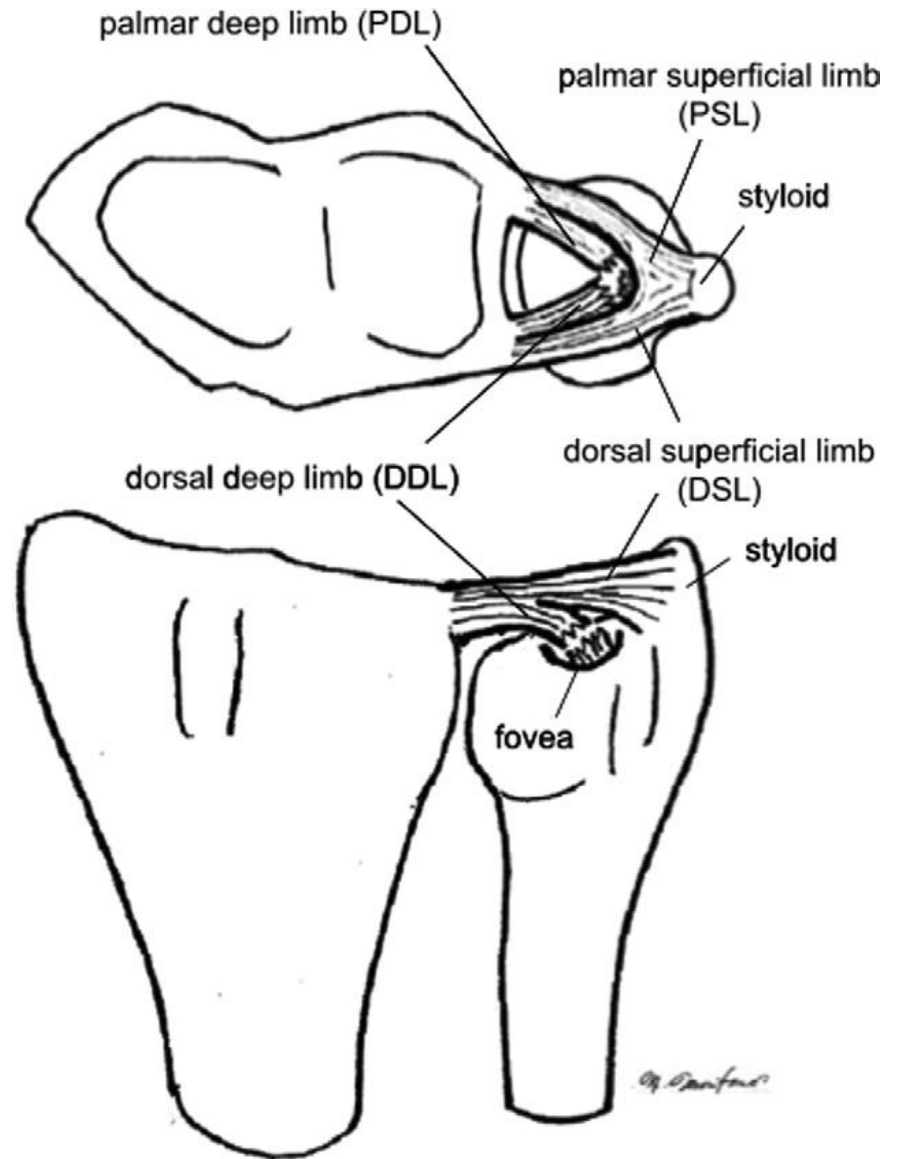
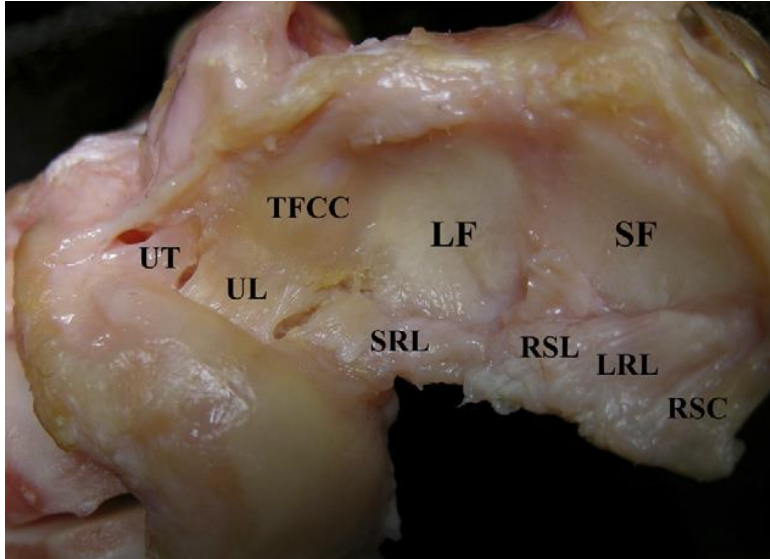
Minor rotational forearm stability, compared with the more biomechanically effective intrinsic radioulna components of the TFC

Intrinsic stabilizers

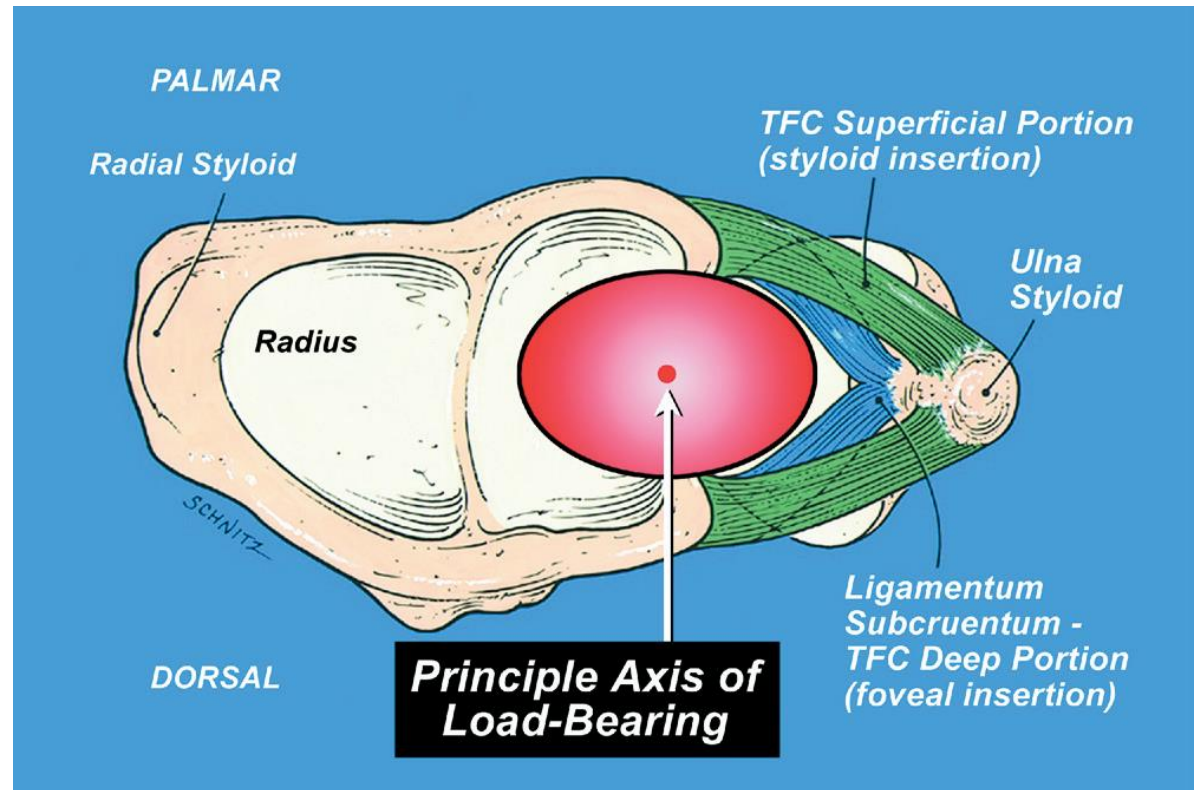
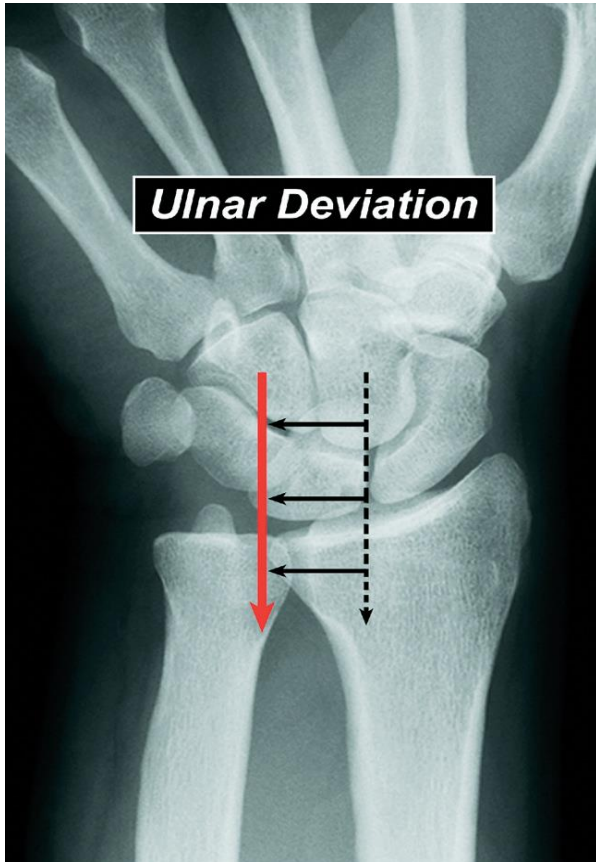

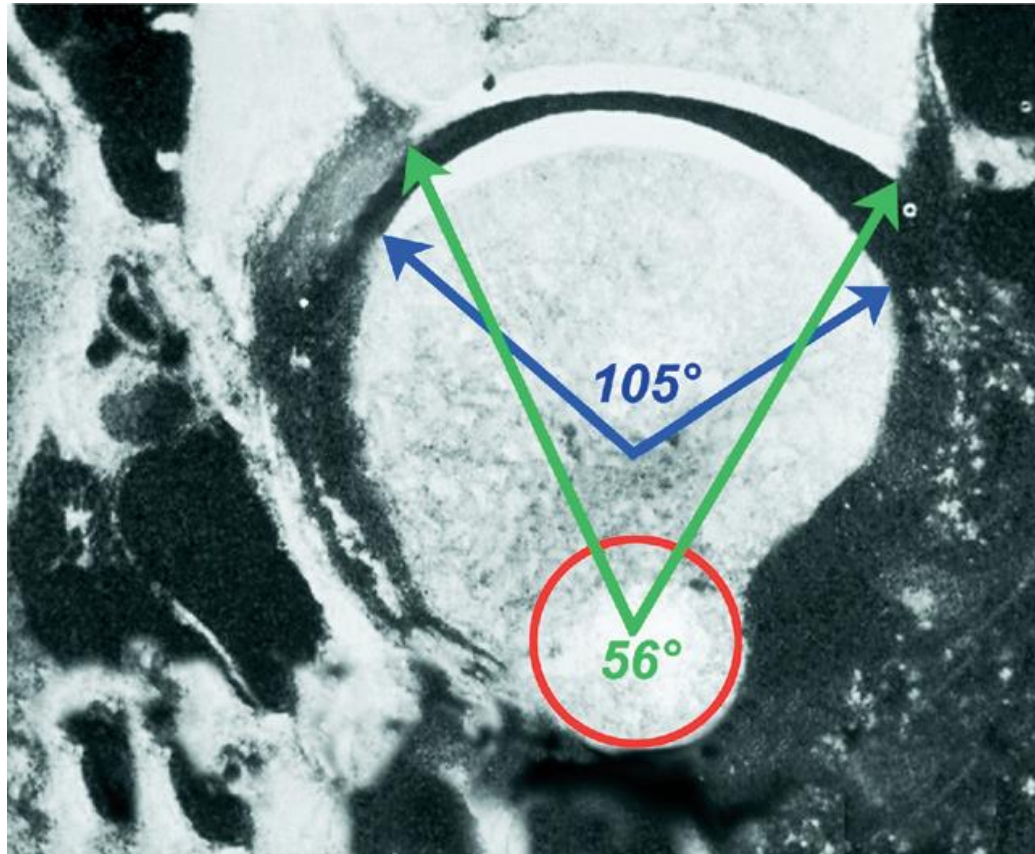
The TFC complex: superficial (green) and deep (blue) radioulna fibers, the two disc-carpal ligaments (disc-lunate and disc-triquetral), and the central articular disc (white).

The articular disc is responsible for transferring load from the medial carpus to the pole of the distal ulna.



DRJU Biomechanics



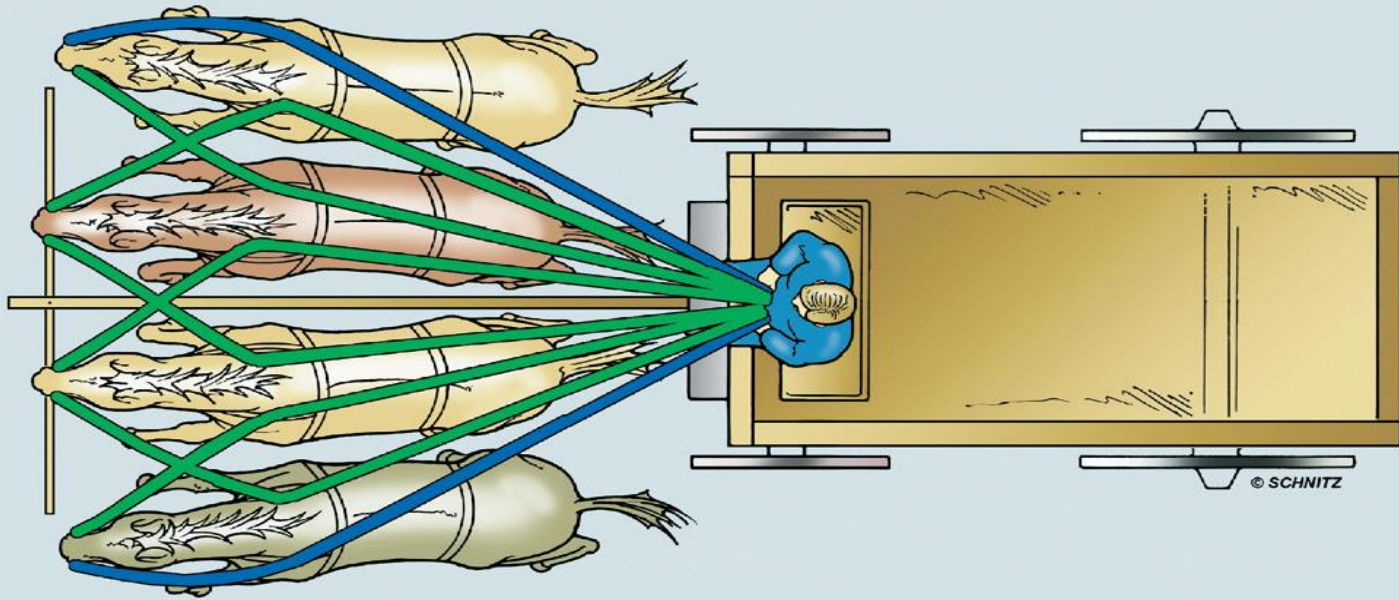


The obtuse angle of attack of the Ligamentum subcrurum (blue) is much more mechanically advantageous in guiding the radius around the seat of the ulna through a full arc of pronosupination.

The superficial radioulna ligaments (green) are much less effective in controlling distal radioulna rotation and translation

The TFC “Buckboard” analogy

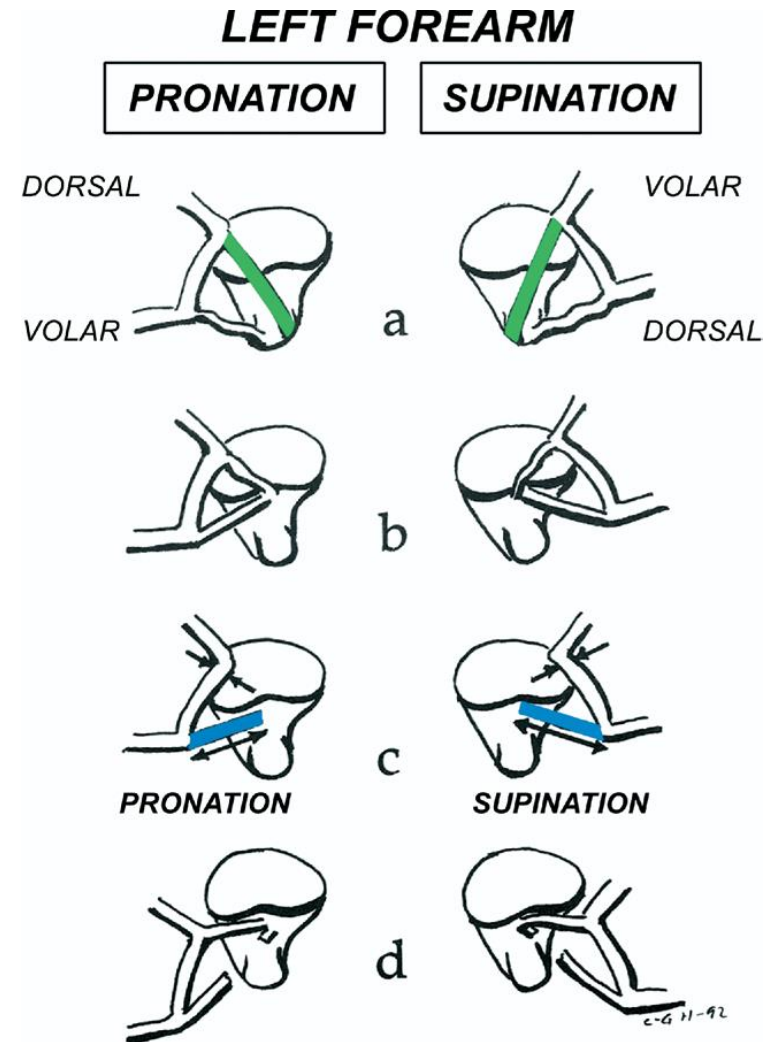
Ligamentum Subcruentum
plus
TFC Superficial Portion



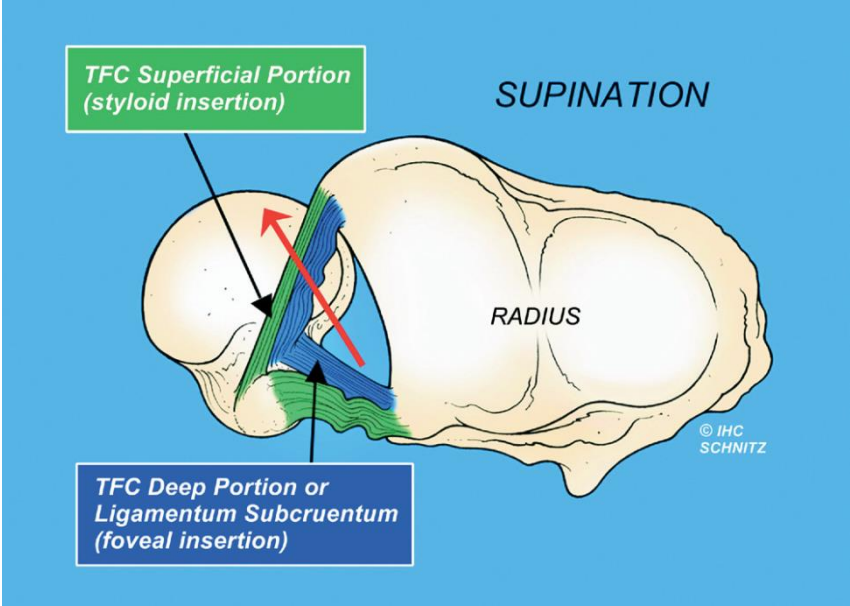
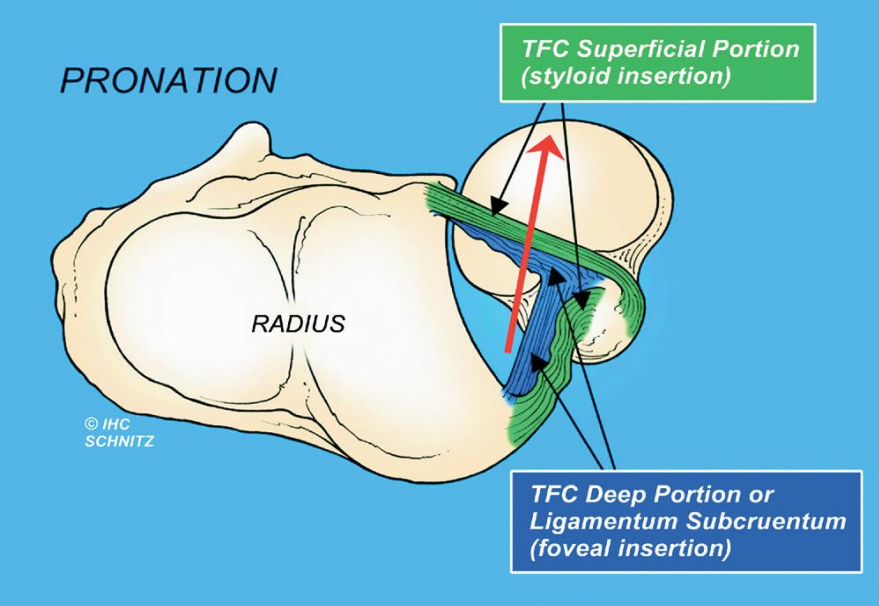
TFCC Biomechanics

In forearm **pronation**, the **dorsal** superficial fibers of the TFC must tighten for stability, as do the deep **palmar** fibers of the Ligamentum subcruentum.

In **supination**, the **palmar** superficial TFC radioulna fibers (to the ulna styloid) tighten, as do the deep **dorsal** fibers of the Ligamentum subcruentum



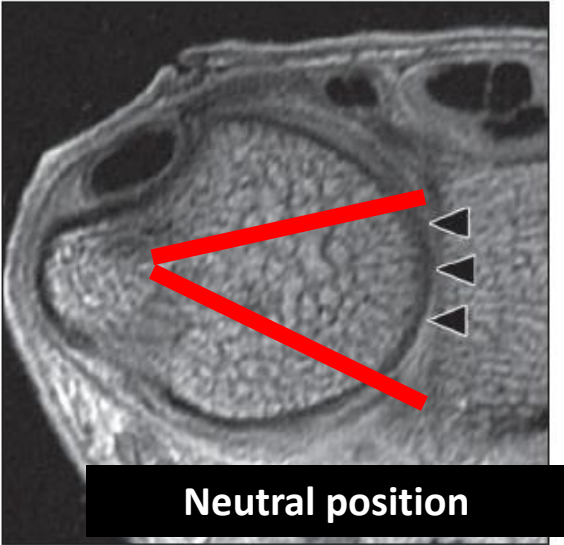
dorsal



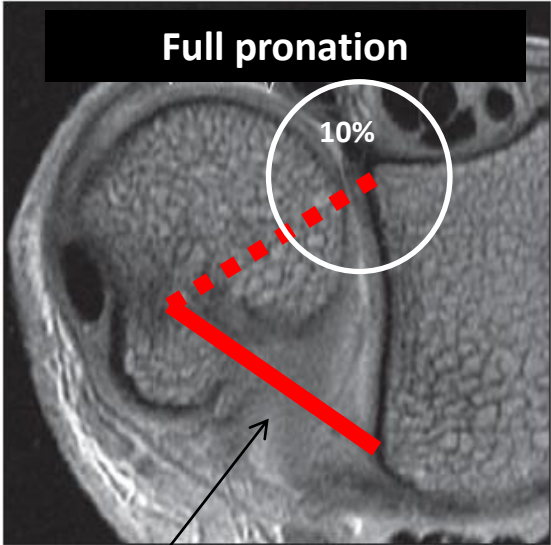
palmar

TFCC Biomechanics

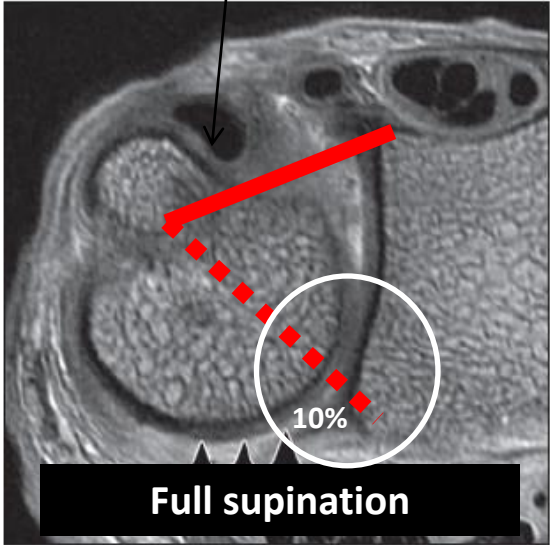
dorsal, deep fibers of the Ligamentum subcruentum



A



B

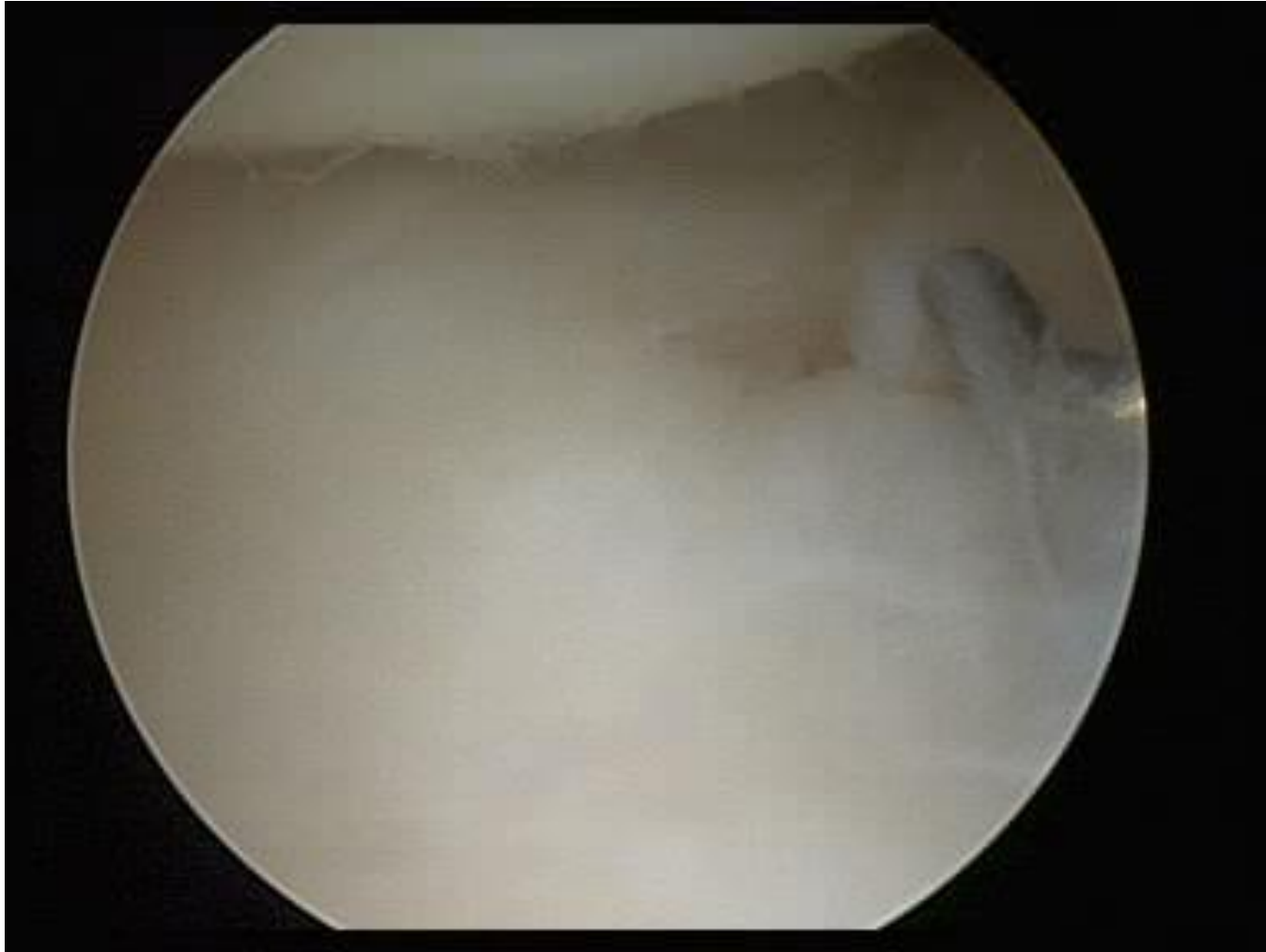


C

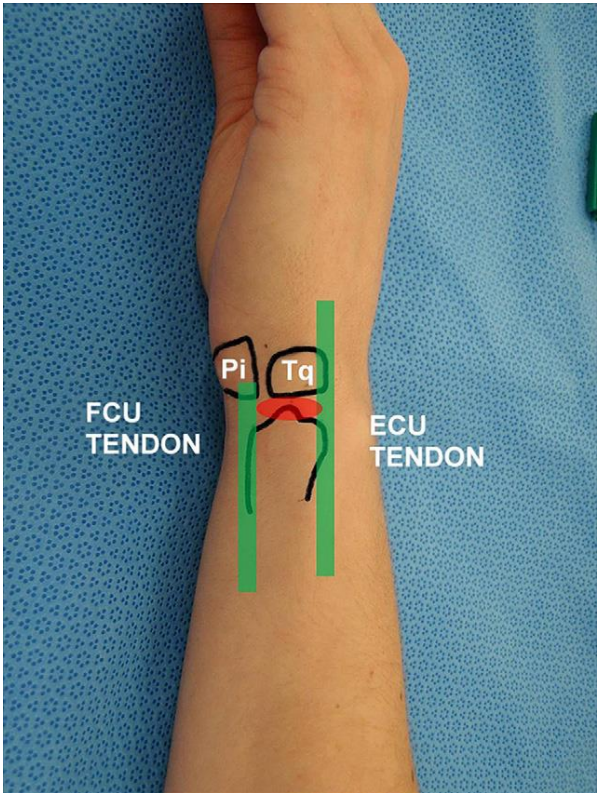
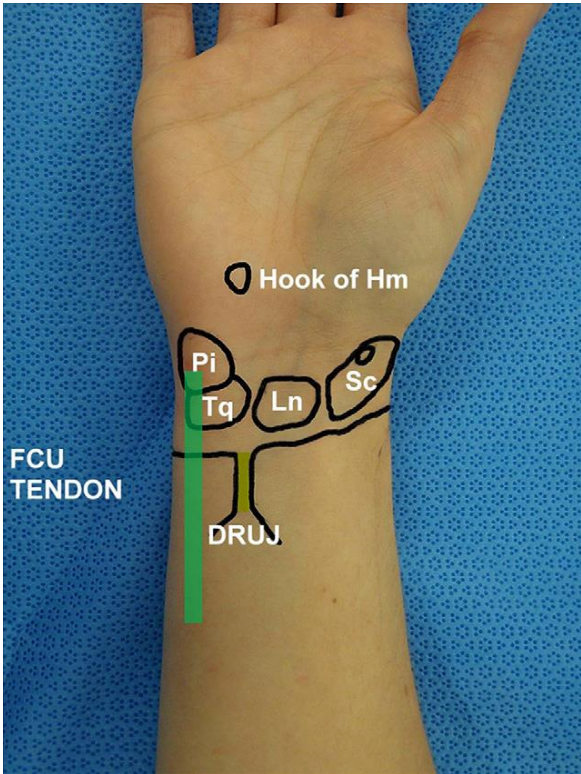
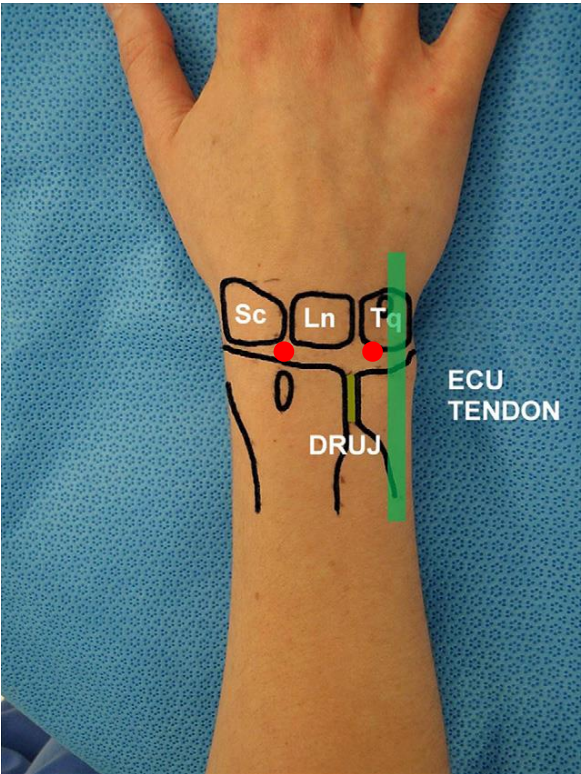
palmar, deep fibers of the Ligamentum subcruentum

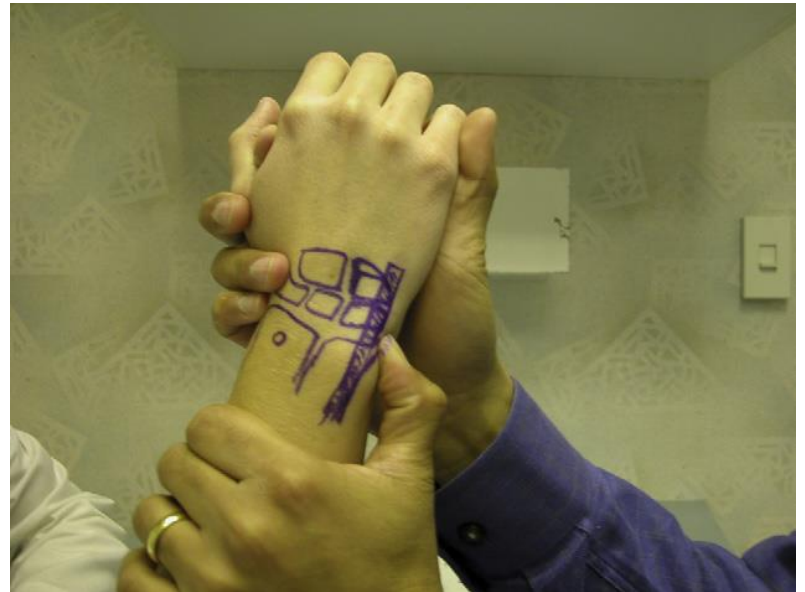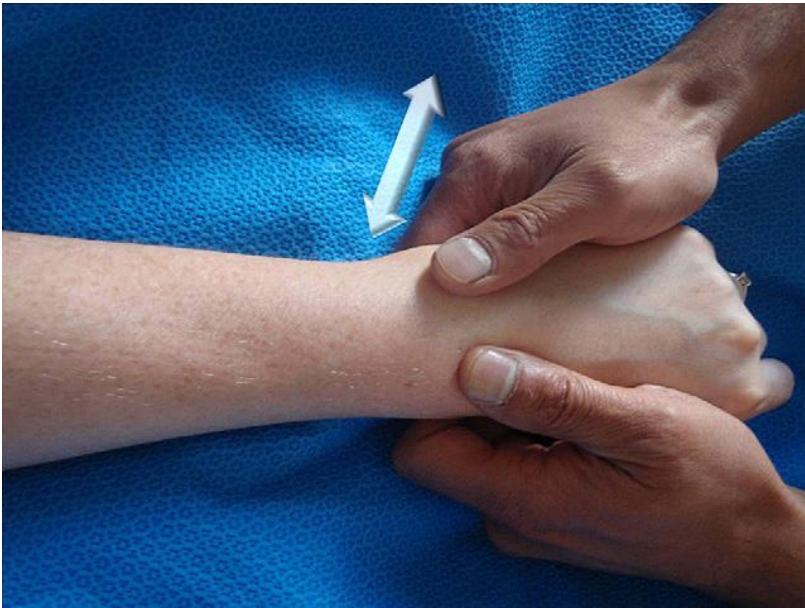Pronation = Palmar

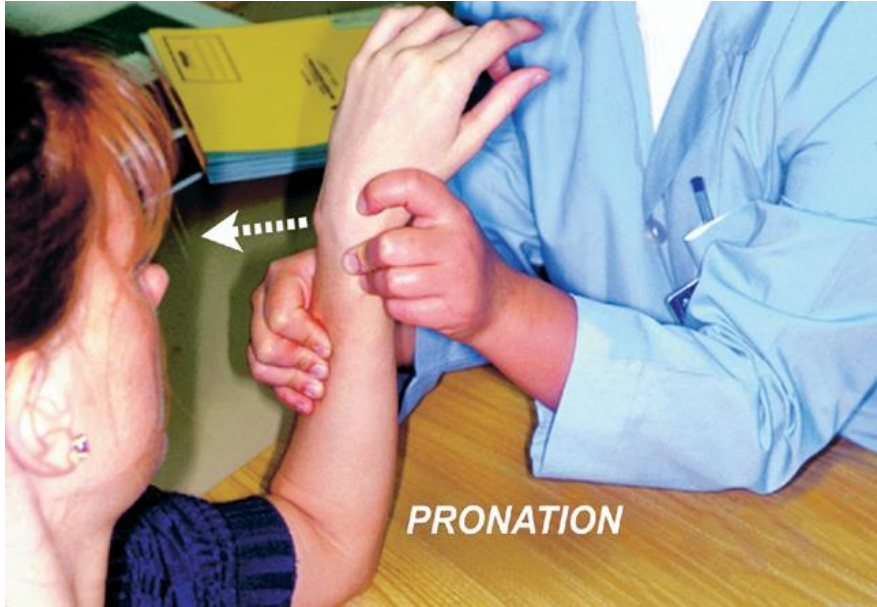Arthroscopic evaluation



Clinical evaluation



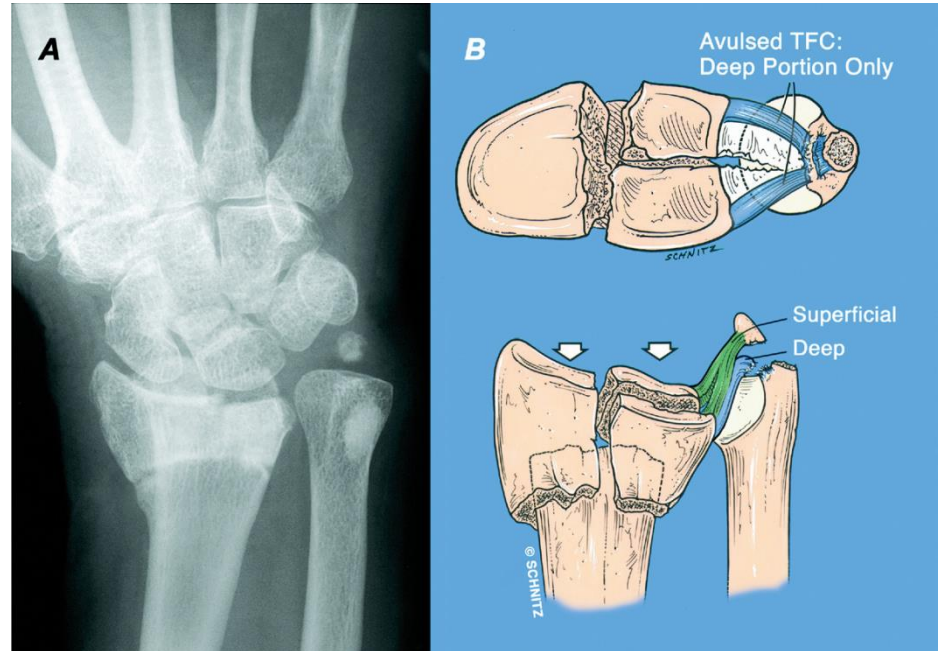


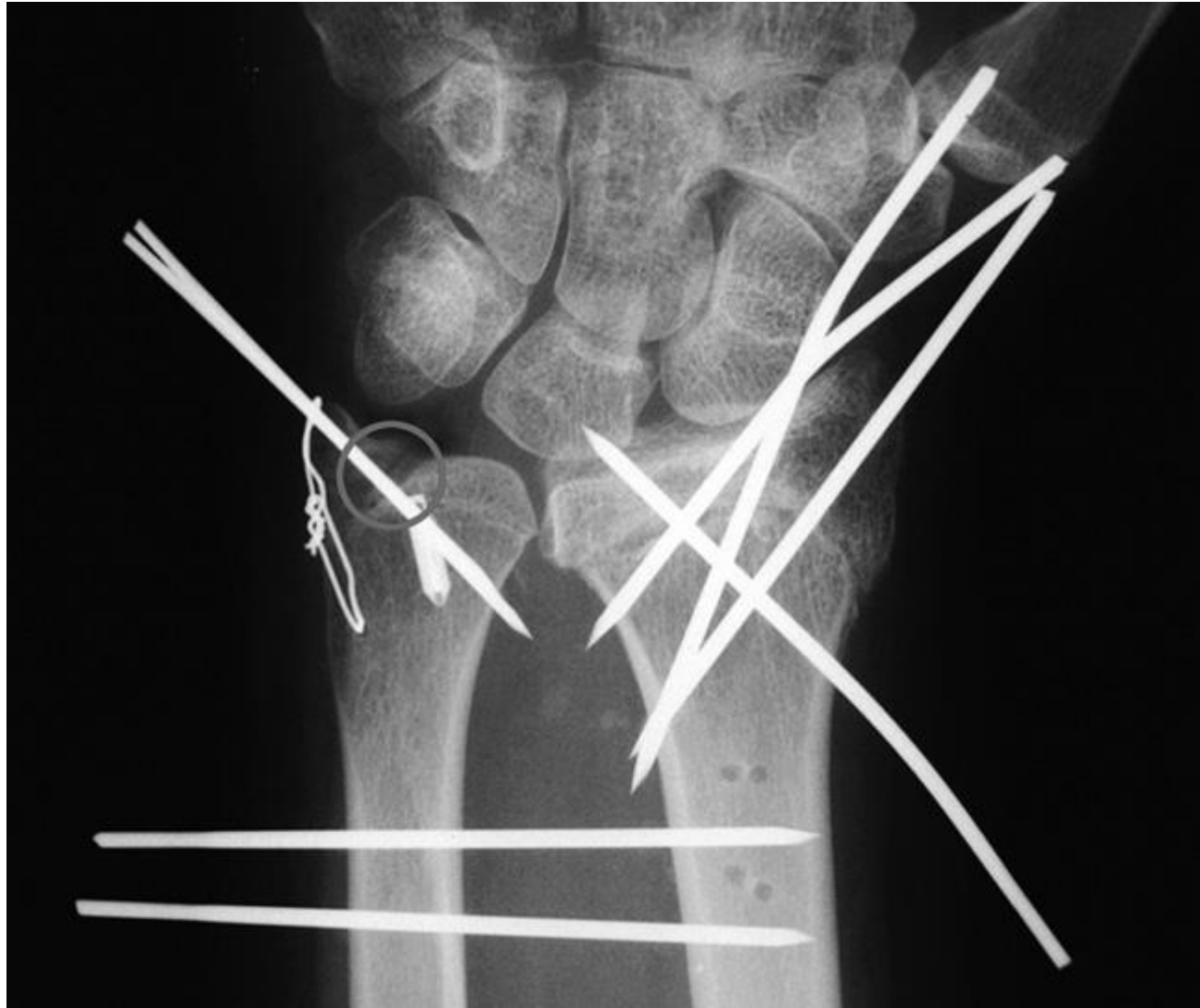

Displaced distal radius fractures

Possible DRUJ instability

- Displaced sigmoid-notch dorsal or volar rim fractures,
- displaced ulnar styloid fractures,
- wide displacement of the DRUJ
- severe radial shortening





TFCC tears

- the most common source of ulnar-sided wrist pain,
- traumatic or degenerative
- foveal tenderness
- fall from height or an object falling against a pronated and extended wrist

Palmer's classifications of triangular fibrocartilage complex lesions

Class 1: traumatic

- | | |
|---|--|
| A | Central perforation |
| B | Ulnar avulsion with or without styloid fracture |
| C | Distal avulsion (from carpus) |
| D | Radial avulsion with or without sigmoid-notch fracture |

Class 2: degenerative

- | | |
|---|--|
| A | TFCC wear |
| B | TFCC wear + lunate/ulnar head chondromalacia |
| C | TFCC perforation + lunate/ulnar head chondromalacia |
| D | TFCC perforation + lunate or ulnar head chondromalacia + LT ligament perforation |
| E | TFCC perforation + lunate/ulnar head chondromalacia + LT ligament perforation + ulnocarpal arthritis |

TFCC = Triangular fibrocartilage complex; LT = Lunotriquetral.

CLASS 1A

The most common traumatic TFCC injury

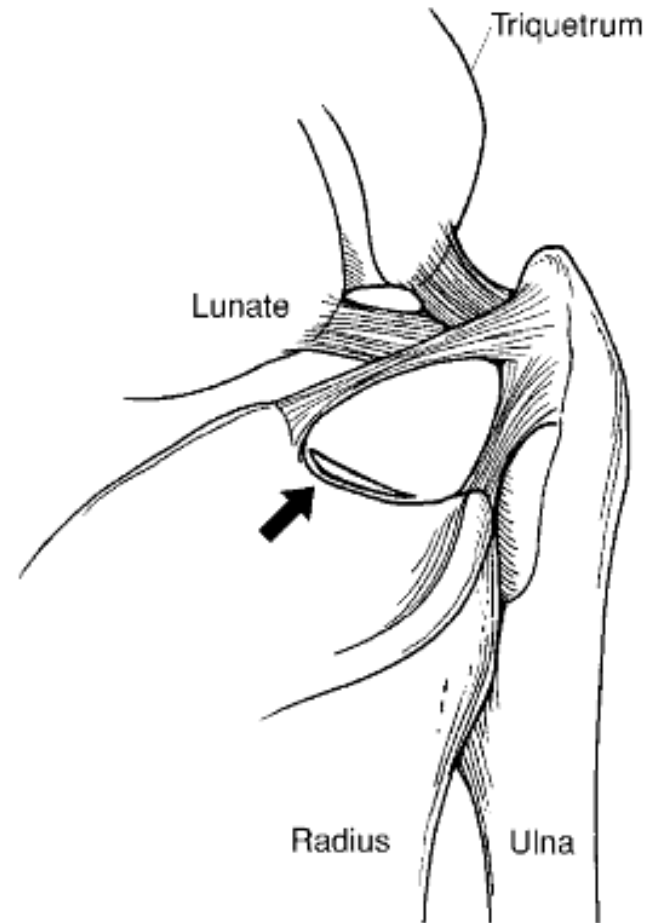
There is a tear or perforation of the central aspect of the disc of the TFCC

Conservative initially (splint), injections

Arthroscopic debridement (to create a stable rim of TFCC)

Success rates range from 66% to 87%

In **ulnarpositive** wrists an ulnocarpal unloading procedure is recommended



CLASS 1B

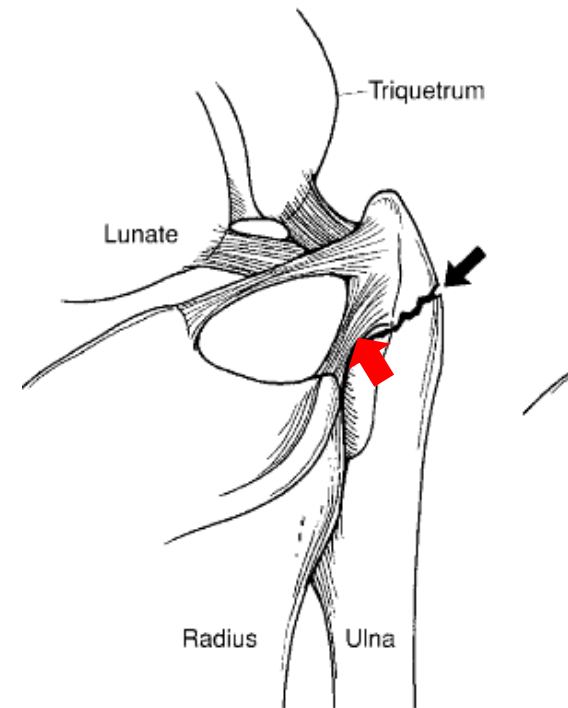
peripheral TFCC tears in the vascular zone of the TFCC with/ or without ulna styloid fracture

open or arthroscopic repair

capsular repair can be performed if the TFCC maintains a normal trampoline effect and if the DRUJ is stable.

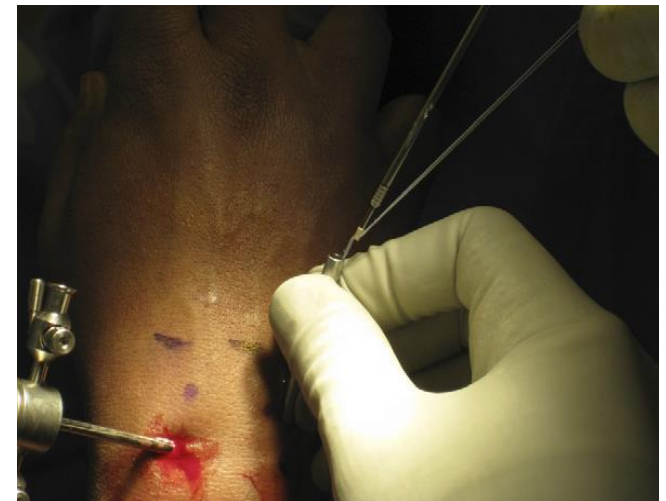foveal repair is recommended in patients with loss of the normal trampoline effect of the TFCC and DRUJ instability.

Success rates up to 90%

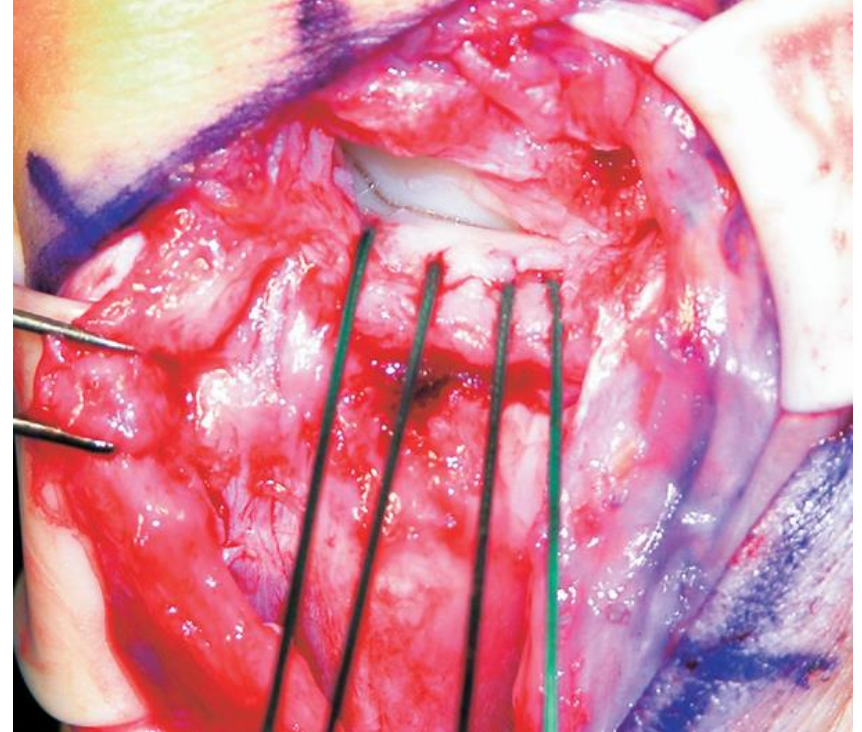
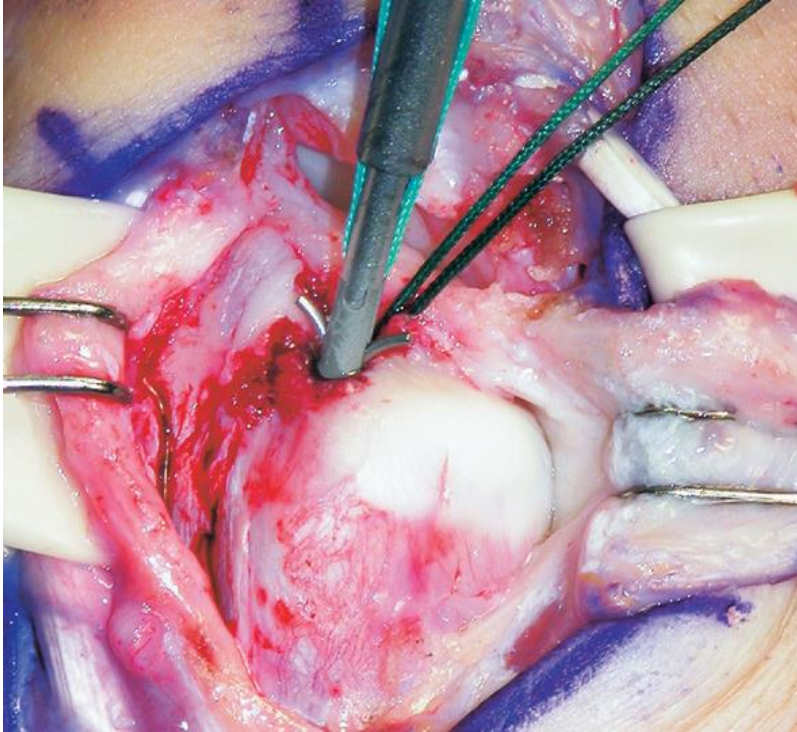


3

c



Foveal repair

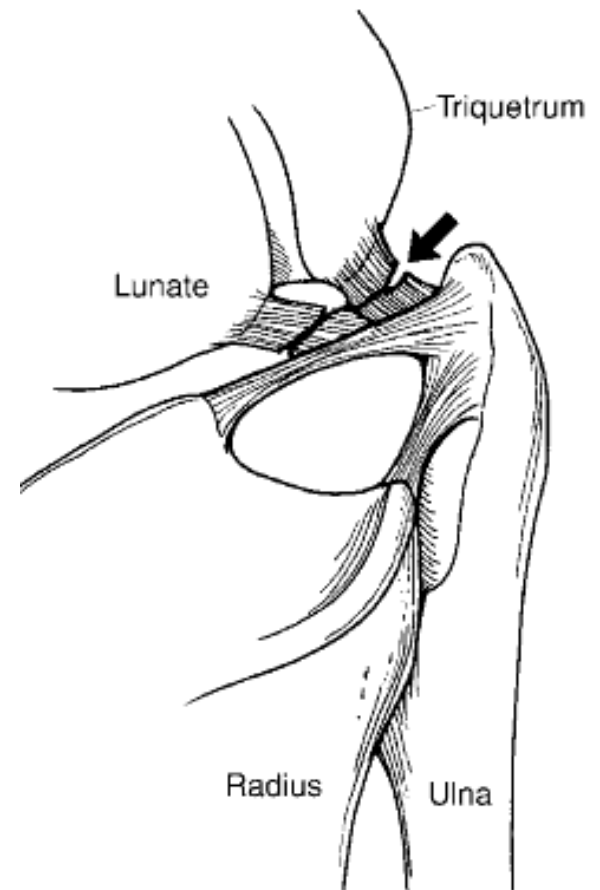


CLASS 1C

Detachment of the TFCC from its distal attachment to the lunate.

These are rare, high-energy injuries that result in ulnocarpal instability and palmar translocation of the ulnar carpus.

Open repair

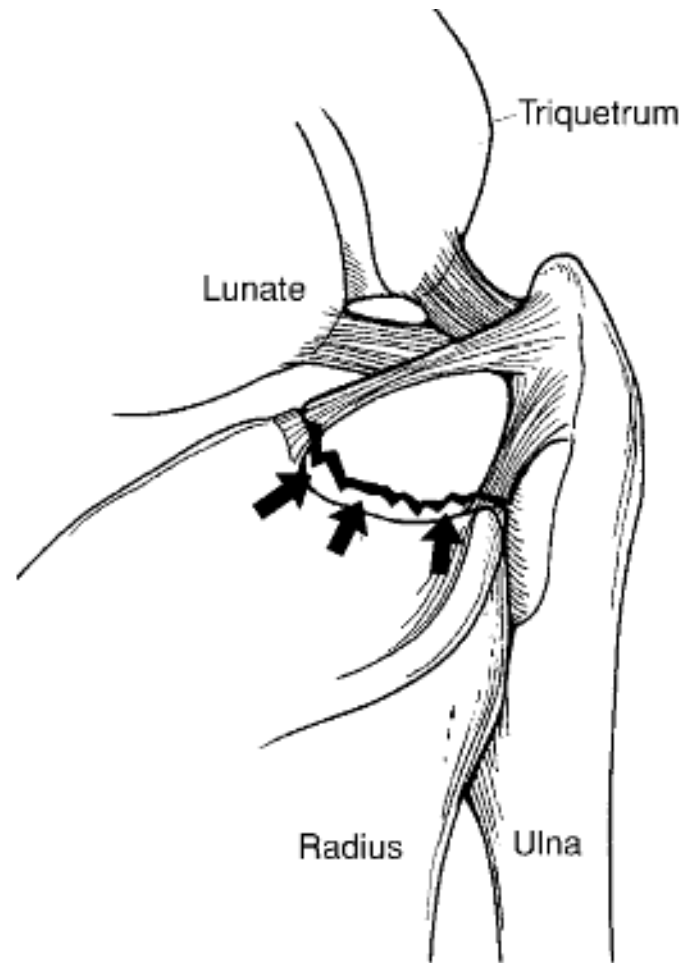


CLASS 1D

Detachment of the TFCC from its radial attachment at the sigmoid notch.

These are far less common and are sometimes confused with class 1A lesions that leave a small rim of TFCC on the radial side.

Associated sigmoid notch fracture

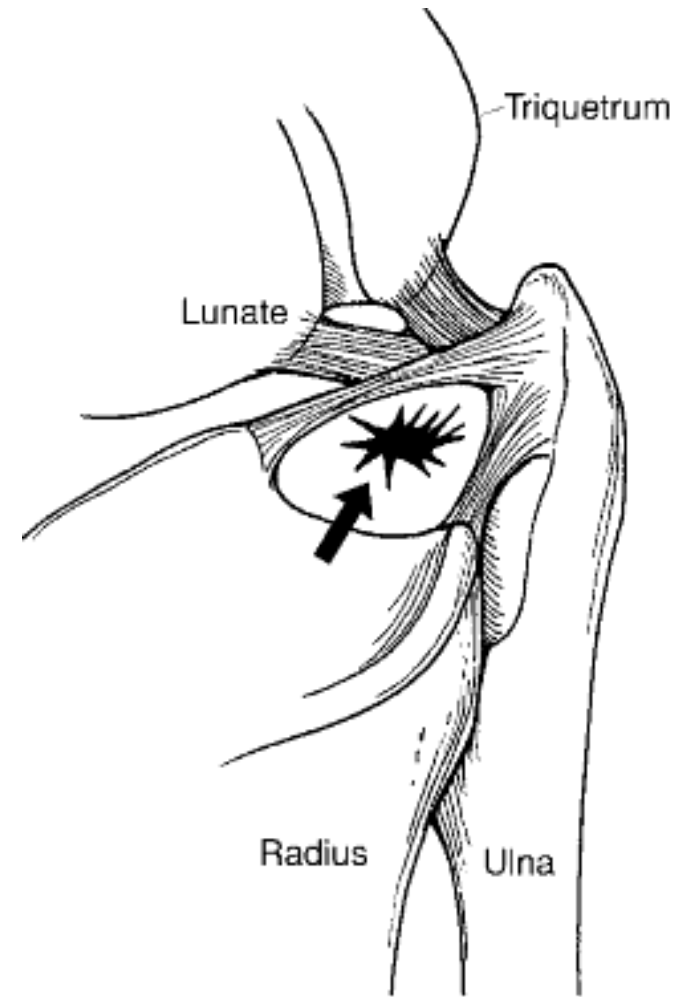


CLASS 2E

Degenerative arthritis of the ulnocarpal joint

Common central disc perforations

Arthroscopic debridement



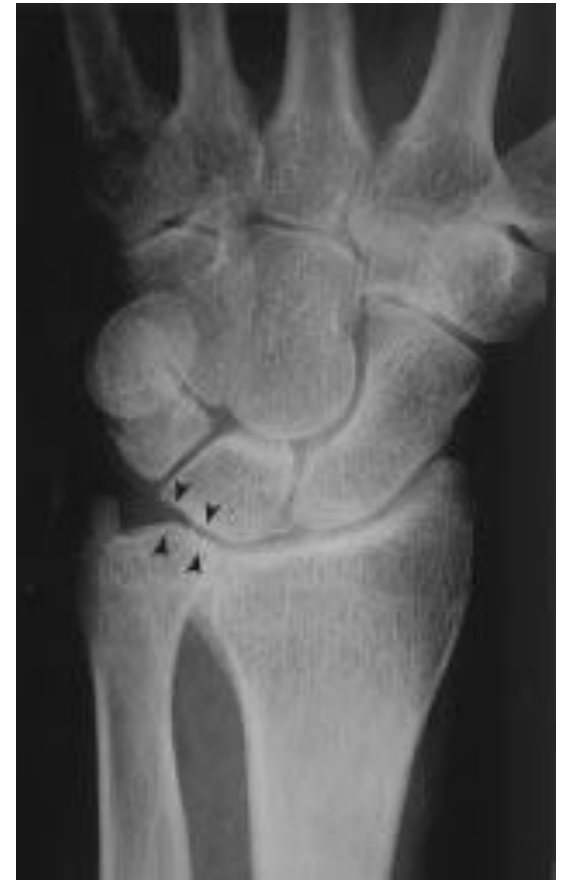Ulnar impaction syndrome

Abutment of the distal end of the ulna or TFCC against the ulnar carpus.

It is associated with positive ulnar variance

In an ulnar neutral wrist, the ulnar carpus absorbs 18% of axial load.

This increases to **42%** when ulnar length is increased 2.5 mm, and decreases to **4.3%** when ulnar variance is decreased 2.5 mm



Ulnar impaction syndrome

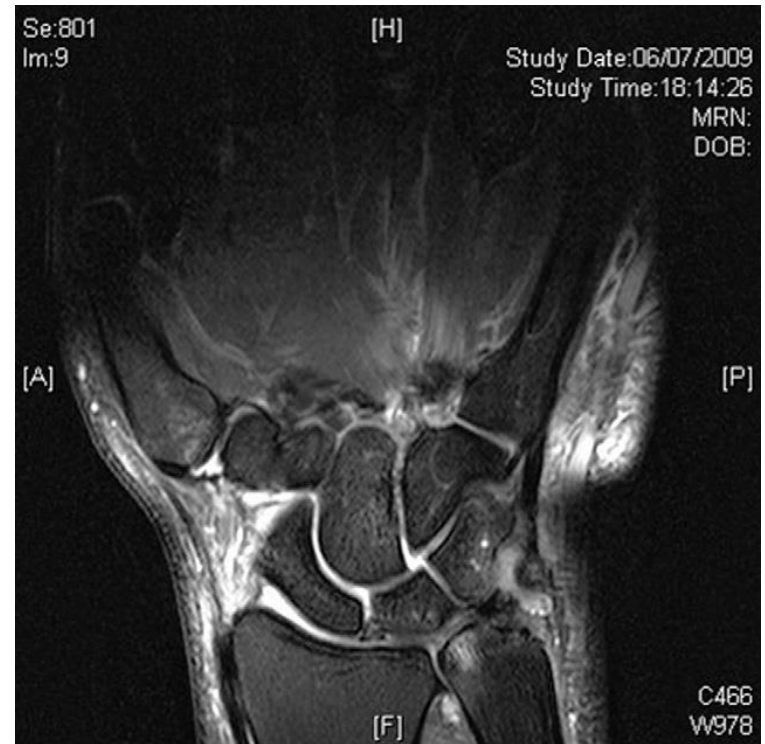
congenital ulna-positive variance,

malunion of the distal radius,

Madelung deformity, (palmar subluxation of the hand, a long distal ulna, and ulnar/palmar angulation of the distal radius)

trauma that affects the growth of the distal radius relative to the ulna,

elbow or forearm trauma such as the radial head injury or Essex-Lopresti injury



Ulnar impaction syndrome

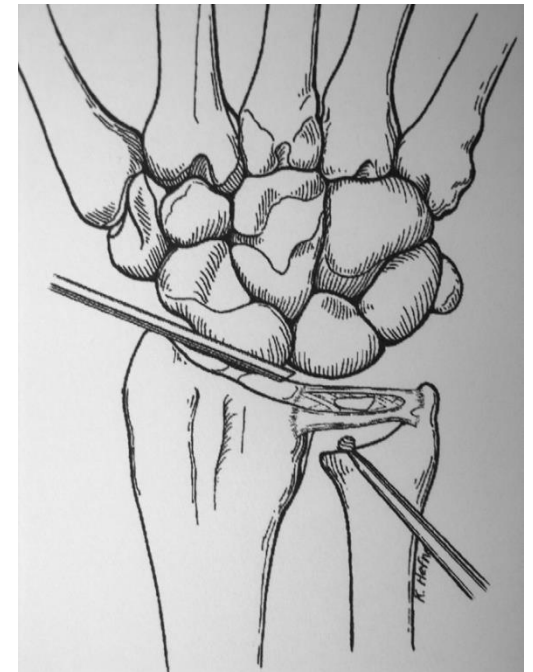
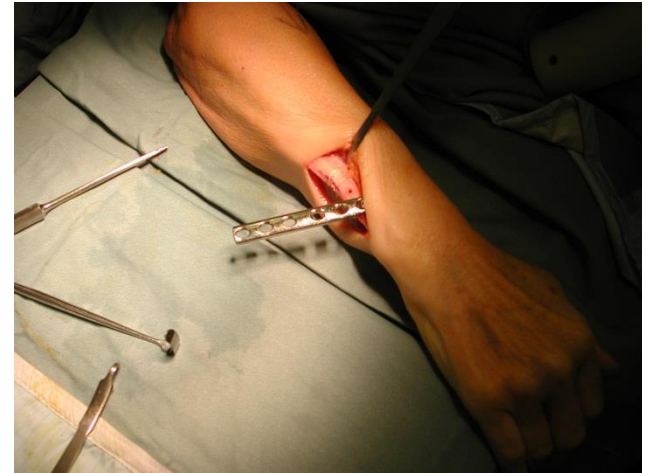Ulnar shortening osteotomy

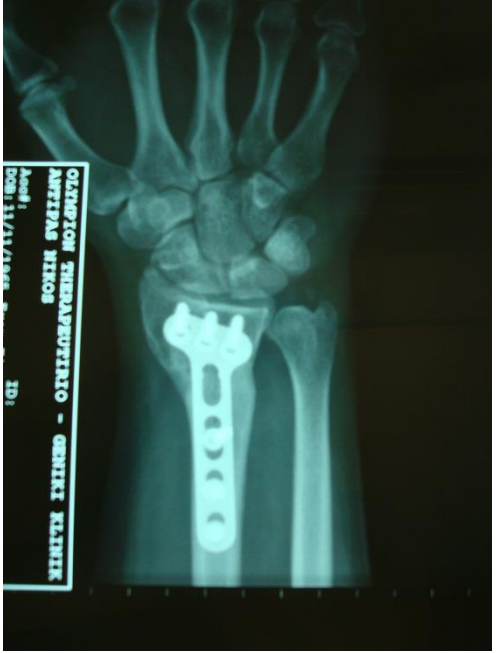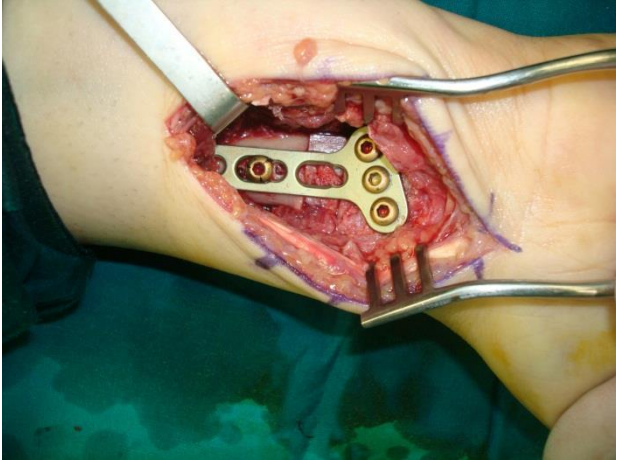
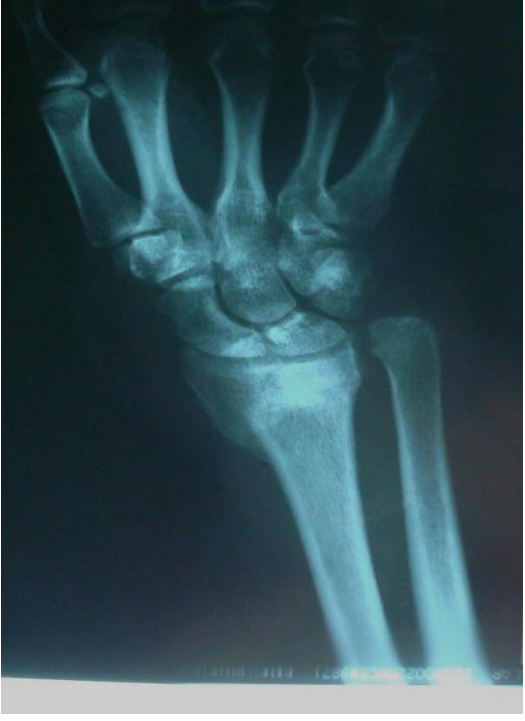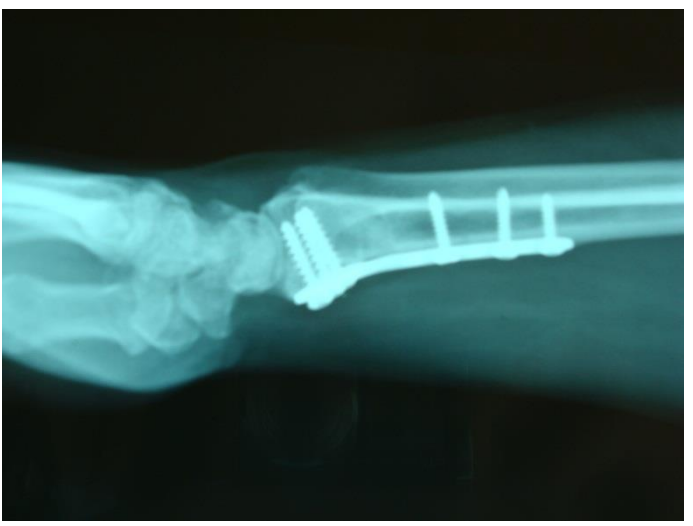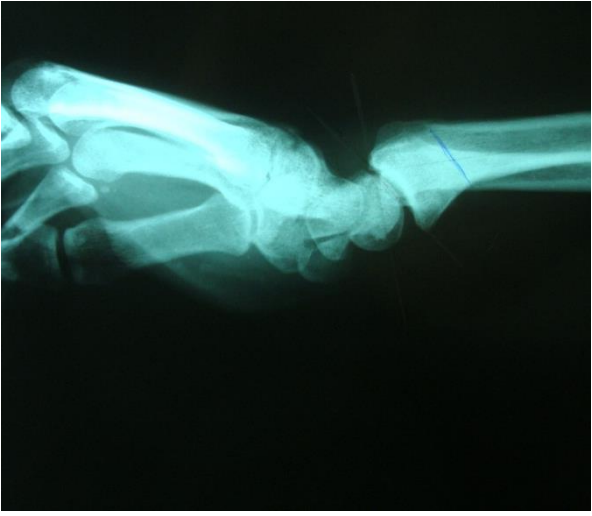Absolute contraindications include established DRUJ arthritis and dorsal DRUJ dislocation, arthritis elsewhere in the wrist

If ulnocarpal impaction is secondary to a **radial malunion**, corrective osteotomy of the radius may be sufficient to correct the radioulnar length discrepancy

Wafer procedure

Open or arthroscopic through the DRUJ portal



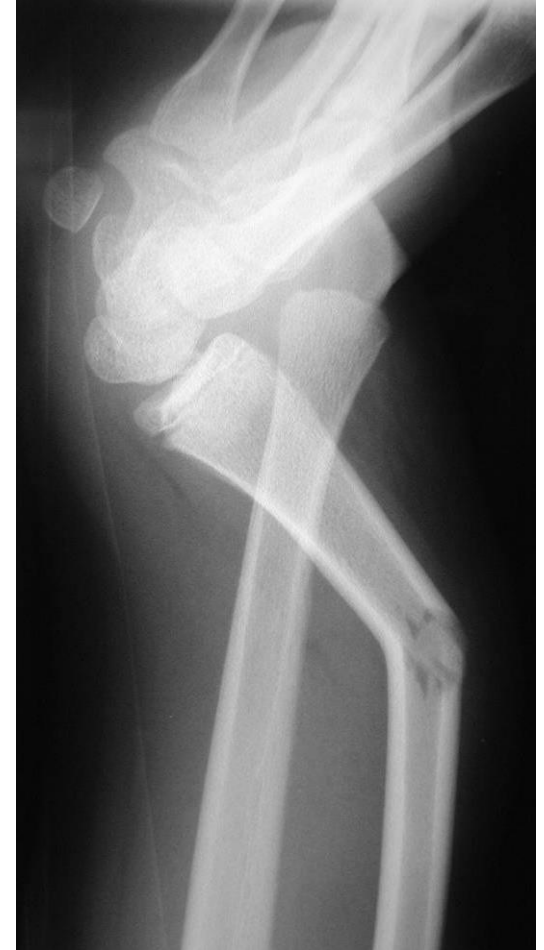

Acute DRJU instability

Fractures of the distal radius.

Galeazzi fractures

Essex-Lopresti injuries are radial-head fractures associated with disruption of the central portion of the IOM, leading to longitudinal instability at the DRUJ

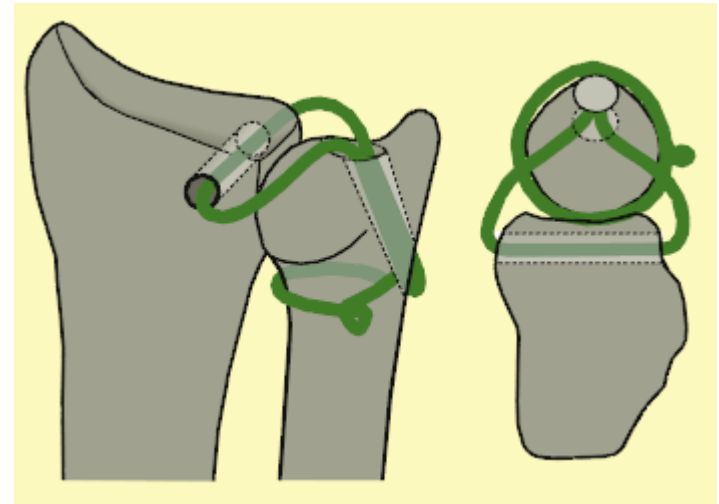


Chronic DRJU instability

- ✓ Isolated TFCC injuries,
- ✓ TFCC injuries with DRUJ dislocation,
- ✓ distal radius fracture,
- ✓ ulnar styloid fracture,
- ✓ Galeazzi fracture or
- ✓ Essex-Lopresti injuries.

Distal radius malunion is the commonest cause of symptomatic DRUJ dysfunction.

Residual dorsal angulation, radial shortening and decreased radial inclination can lead to radio-ulnar incongruity, TFCC distortion and DRUJ instability.



Adams BD, Berger RA. An anatomic reconstruction of the distal radioulnar ligaments for posttraumatic distal radioulnar joint instability. J Hand Surg Am 2002; 27: 243e51

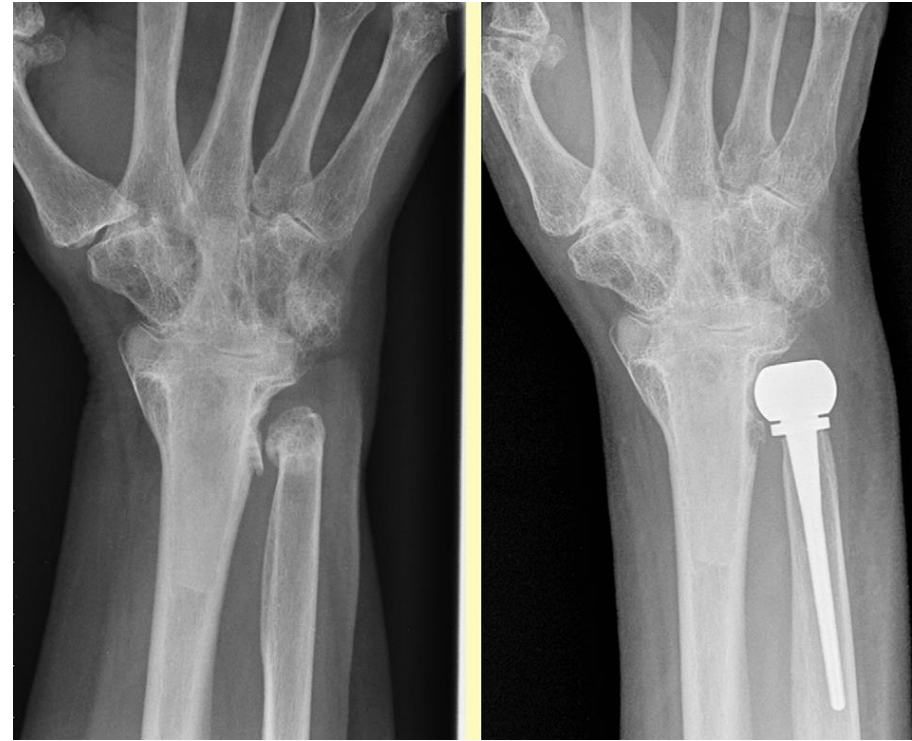
DRJU arthritis

Post-traumatic arthritis,

Inflammatory arthritis,

Osteoarthritis

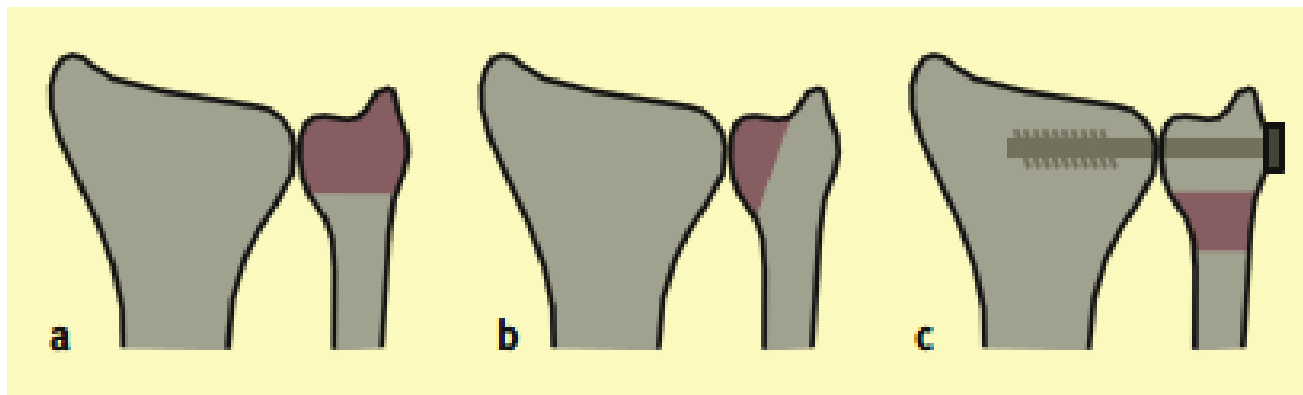
Long-standing DRUJ instability



Darrach's

Hemiresection

Sauve-Kapandji



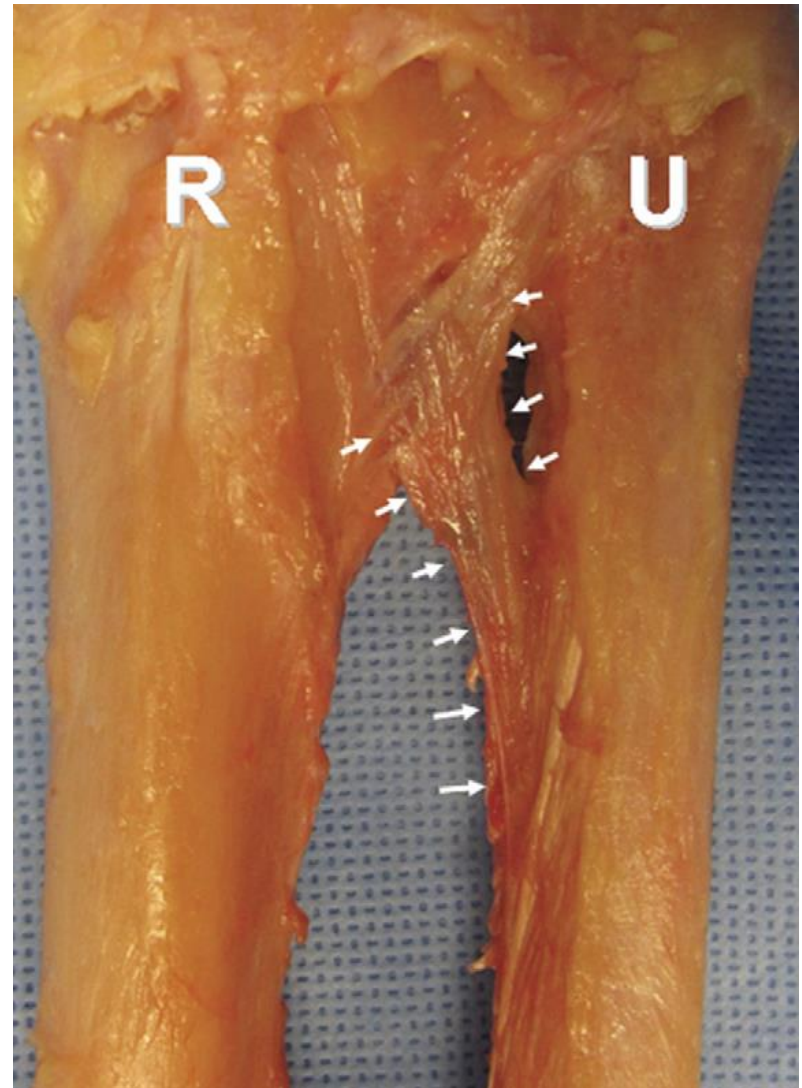
Distal Interosseous Membrane

The DIOM acts as a secondary stabilizer of the DRUJ when the dorsal and palmar radioulnar ligaments of the TFCC are cut.

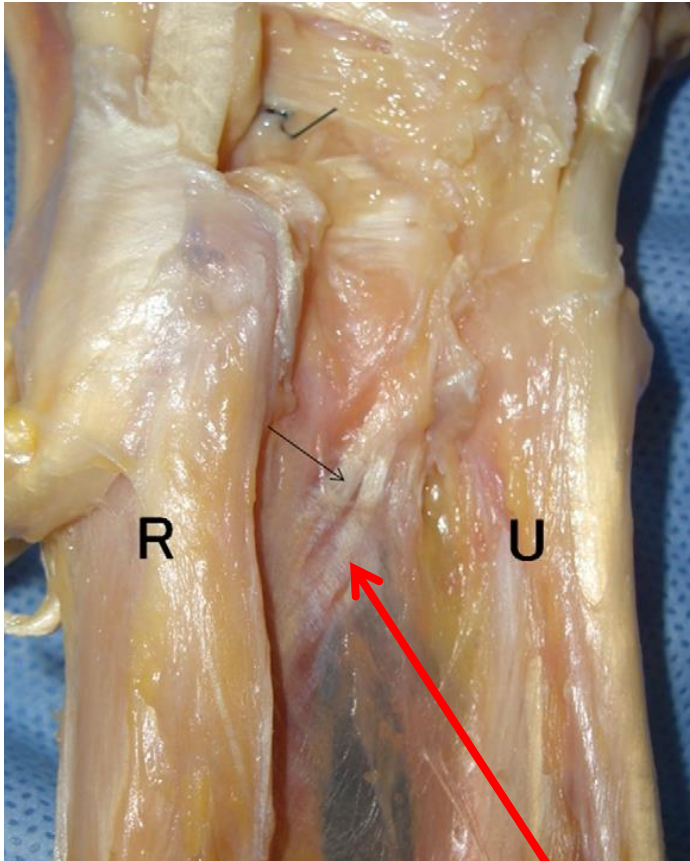
The distal oblique bundle (DOB) exists within the DIOM in 40% of specimens.

DOB is an isometric stabilizer of the forearm during pronosupination.

The presence of a DOB was shown to have a significant impact on DRUJ stability



Distal Interosseous Membrane



The distal radioulnar tract is taut in pronation and loose in supination, which means that this fiber is not isometric.

It was suggested that during pronation, the tract protects the ulnar head in a sling

The **distal radioulnar tract** extends from the radial shaft proximally to the dorsal capsule of the distal radioulnar joint distally.

Biomechanics in pronosupination

The distal 3 ligaments

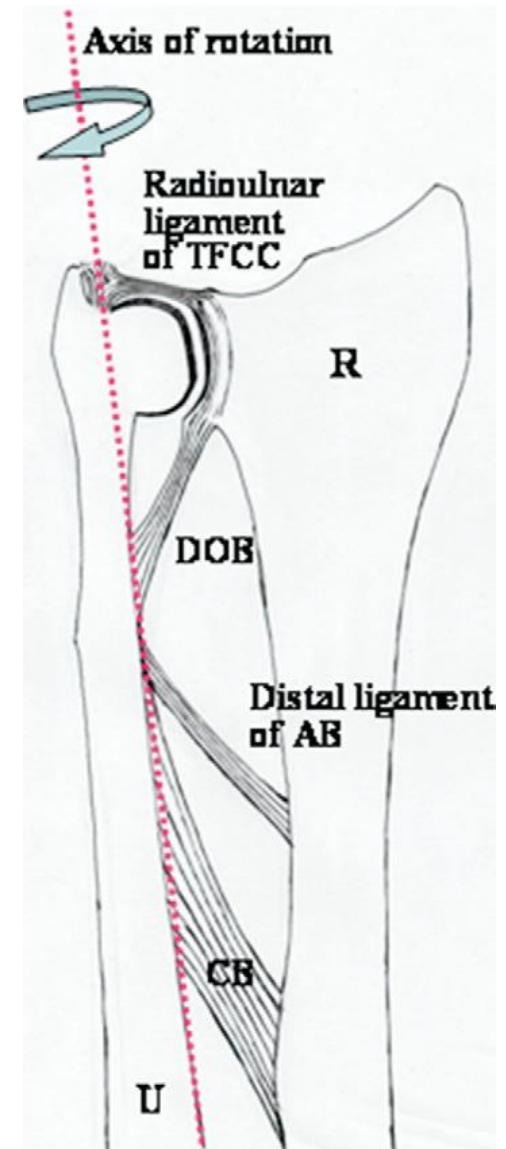
- **central band,**
- **accessory band**
- **DOB**

had little change in length during forearm rotation, with their ulnar attachments located almost on the axis of forearm rotation

The 2 proximal ligaments changed substantially in length, with their attachments out of the course of the axis.

The distal 3 ligaments of the IOM are essentially isometric stabilizers of the forearm.

Moritomo H, et al. J Hand Surg 2009;34A:685–691.



DRUJ laxity and DOB

DRUJ laxity was greater in the group without a DOB than in the group with a DOB. That study hypothesized that DRUJ laxity depends at least in part on the presence and configuration of the DIOM.

Kitamura T, Moritomo H, Arimitsu S, Berglund LJ, Zhao KD, An KN, et al. The biomechanical effect of the distal interosseous membrane on distal radioulnar joint stability. *J Hand Surg* 2011;36A:1626–1630.

Stabilizing effect of the DIOM on ulnar shortening

Longitudinal resistance to ulnar shortening was significantly greater in proximal shortening

> stability of DRUJ with even **1 mm** of shortening in comparison with distal shortening (4 mm)

